

UNIVERSITY OF BOLTON

FACULTY OF HEALTH AND WELLBEING

MSc ADVANCED PRACTICE
ADVANCED PROFESSIONAL DEVELOPMENT

SEMESTER ONE EXAMINATION 2018/2019

ACUTE MEDICINE

MCQ PAPER

MODULE NO: HLT7089

Date: Wednesday 16 January 2019

Time: 2.00 pm – 3.30 pm

INSTRUCTIONS TO CANDIDATES:

There are 50 questions.

Answer ALL 50 questions.

There are 2 marks for each question.

There are a total of 100 marks available.

The pass mark is 50%.

Faculty of Health and Wellbeing
MSc Advanced Practice/Advanced Professional Development
Semester One Examination 2018/2019
Acute Medicine
Module No: HLT7089

1. A 52-year-old man is referred to the AMU with a 12-hour history of increasingly severe central chest pain. He describes the pain as a sharp, tearing pain which radiates through to his back and between his shoulder blades. The patient looks in pain and his BP is 210/123. What is the most likely diagnosis?
 - a. Myocardial ischaemia
 - b. Pulmonary embolism
 - c. Pneumonia
 - d. Angina
 - e. Thoracic aortic dissection

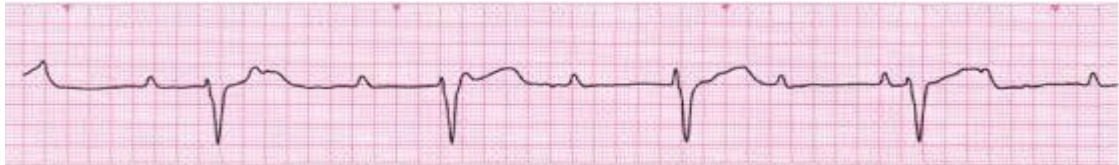2. Which of the following answers would **not** cause a D-dimer level to be raised?
 - a. Tension headache
 - b. Sepsis
 - c. Malignancy
 - d. Pulmonary Embolism
 - e. Recent Surgery

3. A 58 year old gentleman is referred to the AMU with a 3 hour history of central crushing chest pain that radiates to his left arm. He is nauseated and clammy. The ECG shows ST elevation in the II, III and AVF. Which is the most likely coronary artery to be occluded?
 - a. Right coronary artery
 - b. Left anterior descending artery
 - c. Left circumflex artery
 - d. Posterior descending artery
 - e. Right marginal artery

Please turn the page

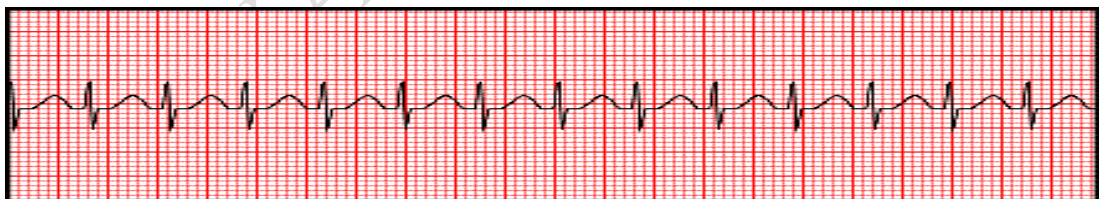Faculty of Health and Wellbeing
MSc Advanced Practice/Advanced Professional Development
Semester One Examination 2018/2019
Acute Medicine
Module No: HLT7089

4. An 83 year old man was admitted following a witnessed episode of transient loss of consciousness. On examination, his pulse is 32 bpm and his BP is 89/47. The cardiac monitor shows:



What is the heart rhythm?

- a. Atrial flutter
 - b. First degree AV block
 - c. Sinus rhythm
 - d. Mobitz type II heart block
 - e. Complete heart block
5. A 26 year old lady is referred to the AMU by her GP following a sudden episode of rapid and regular palpitations which had self-terminated after 5 minutes. On admission, her palpitations have returned and the cardiac monitor below shows:



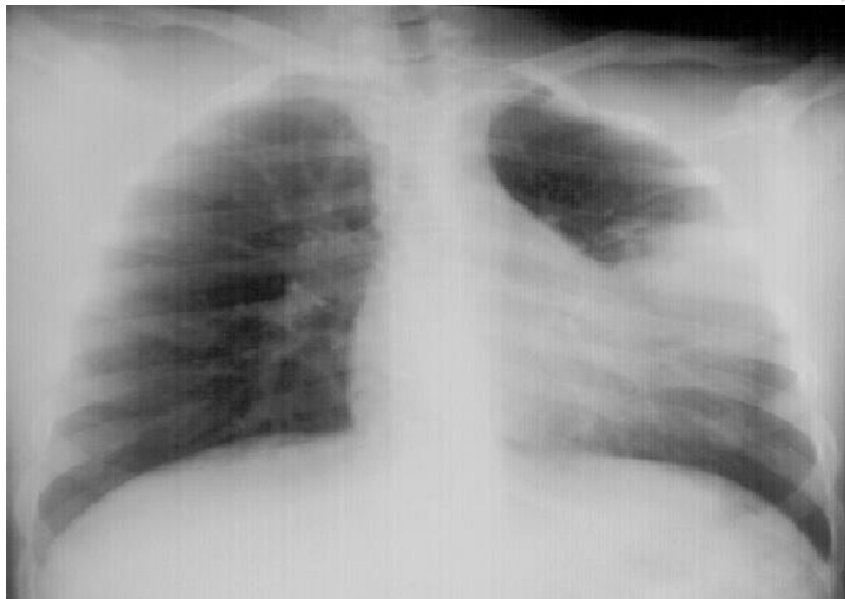
Her BP is 110/64, she is not breathless and she has no chest pain. A junior doctor has performed carotid sinus massage and vaso-vagal manoeuvres which have made no difference to her heart rate. What would be the next step in her management?

- a. Synchronised DC shock
- b. IV Verapamil
- c. Betablocker
- d. IV Adenosine
- e. Repeat vaso-vagal manoeuvres

Faculty of Health and Wellbeing
MSc Advanced Practice/Advanced Professional Development
Semester One Examination 2018/2019
Acute Medicine
Module No: HLT7089

Please turn the page

6. A 48 year old man is admitted to the AMU with a five day history of exertional breathlessness, productive cough with green phlegm and fever. On examination, his respiratory rate is 22/min, oxygen saturations are 97% on air, his pulse is 92 bpm and regular and his blood pressure is 112/56. The CXR shows:



What is the next line in the management for this patient?

- a. Oxygen
- b. Oral antibiotics
- c. IV antibiotics
- d. IV diuretics
- e. IV fluids

Please turn the page

Faculty of Health and Wellbeing
MSc Advanced Practice/Advanced Professional Development
Semester One Examination 2018/2019
Acute Medicine
Module No: HLT7089

7. According to the CURB-65 criteria, which of the below is indicative of an increased mortality risk?
- Male sex
 - BP
 - Age
 - WCC
 - CRP
8. An 82 year old lady with a history of ischaemic heart disease, is admitted to AMU after waking breathless with chest heaviness. On examination, her respiratory rate is 32/min, oxygen saturations are 96% on 15L O₂ via non-rebreath mask, her pulse is 128 bpm and regular and her blood pressure is 111/58. On examination of her chest there are bilateral fine inspiratory chest crackles up to the mid zones and her JVP is raised. What would be your immediate management?
- IV Paracetamol
 - IV diuretics
 - GTN infusion
 - ACE inhibitor
 - IV fluids
9. A 28 year old man is admitted with a 5 week history of progressive breathlessness and joint pain. For the past two days he has noticed tender red swellings to his legs. On examination, the "swellings" are typical of erythema nodosum. What would be the most likely diagnosis based on the history?
- Sarcoidosis
 - Arterial insufficiency
 - Rheumatoid arthritis
 - Asthma
 - Cor Pulmonale

Please turn the page

Faculty of Health and Wellbeing
MSc Advanced Practice/Advanced Professional Development
Semester One Examination 2018/2019
Acute Medicine
Module No: HLT7089

10. A 19 year old lady with a history of Asthma, was admitted with severe breathlessness and wheeze. A peak flow reading was obtained to determine the severity of an Asthma exacerbation. To support diagnosis, life threatening Asthma using PEFr in conjunction with clinical findings is defined by NICE (2018) as:

- a. PEFr 50% best or predicted
- b. PEFr 40% best or predicted
- c. PEFr 35% best or predicted
- d. PEFr 33% best or predicted
- e. PEFr 30% best or predicted

11. On a CXR for pneumonia you will see:

- a. Bullae
- b. Kerley B lines
- c. Bilateral lymphadenopathy
- d. Widened mediastinum
- e. Consolidation

Please turn the page

Faculty of Health and Wellbeing
 MSc Advanced Practice/Advanced Professional Development
 Semester One Examination 2018/2019
 Acute Medicine
 Module No: HLT7089

12. A 75 year old man is admitted with following an acute exacerbation of COPD. He has been treated with Salbutamol and Ipratropium Nebulisers, IV Steroids and controlled O₂ at 28%. He is now tiring. His ABG is repeated following treatment after one hour which shows:

	On admission (air)	At 1 hour (28%)	Normal values
pH	7.34	7.26	7.35 - 7.45
PO ₂	7	9	10 - 14 kPa
PCO ₂	6	9	4.5 - 6.0 kPa
BE	-3	-6	-2 – 2 mmol/l

What is the next step in the management for this patient?

- Increase O₂ to 35%
 - Request urgent CTPA
 - IV Dopram
 - Reduce O₂ to 24%
 - Trial of non-invasive positive pressure ventilation
13. A 36 year old man presents with a night time cough and wheezing over the past 2 months. He has a previous history of eczema. What finding in his full blood count would be fitting with the scenario and help towards his diagnosis?
- Basophilia
 - Eosinophilia
 - Lymphocytosis
 - Monocytosis
 - Neutrophilia

Please turn the page

Faculty of Health and Wellbeing
MSc Advanced Practice/Advanced Professional Development
Semester One Examination 2018/2019
Acute Medicine
Module No: HLT7089

14. A 48 year old nurse is admitted with intermittent epigastric pain and two episodes of dark stools. She describes the pain as “heart burn” that eases when she eats but is worse when she goes to bed at night. Her blood tests today show:

		Normal values
Hb	94	(130 – 180)
WCC	8.0	(3.6 – 11.0)
PLT	520	(140 – 400)
MCV	85	(80 – 100)
Urea	13	(2.5 – 7.8)

What is the most likely cause of the upper GI bleed?

- a. Duodenal ulcer
- b. Oesophageal varices
- c. Mallory Weis tear
- d. Gastric ulcer
- e. Ulcerative colitis

15. According to Truelove and Witts criteria, which of the below parameters constitutes a flare of ulcerative colitis?

- a. <2 bowel motions per day with large amounts of rectal bleeding
- b. Between 2 and 4 bowel motions per day with large amounts of rectal bleeding
- c. >4 bowel motions per day with large amounts of rectal bleeding
- d. >5 bowel motions per day with large amounts of rectal bleeding
- e. >6 bowel motions per day with large amounts of rectal bleeding

Please turn the page

Faculty of Health and Wellbeing
MSc Advanced Practice/Advanced Professional Development
Semester One Examination 2018/2019
Acute Medicine
Module No: HLT7089

16. A 45 year old lady presents with right upper quadrant abdominal pain, vomiting and fever. The pain sometimes radiates to her right shoulder. The Liver function test results today are:

		Normal results
Bilirubin	19	(<21)
ALT	69	(<33)
ALP	192	(30 – 130)
WCC	18	(3.6 – 11.0)
CRP	132	(<5)
Amylase	52	(28 – 100)

What of these answers is a likely diagnosis?

- a. Cholecystitis
- b. Budd Chiari syndrome
- c. Pancreatitis
- d. Acute hepatitis
- e. Irritable bowel disease

17. A 23 year old lady is diagnosed with iron deficiency anaemia. Which of the following blood pictures would fit with her diagnosis?

Normal = Hb 115-165, MCV 80-100, MCH 27-32

- a. Hb 92, MCV 72, MCH 32
- b. Hb 92, MCV 85, MCH 30
- c. Hb 92, MCV 104, MCH 24
- d. Hb 92, MCV 72, MCH 24
- e. Hb 92, MCV 85, MCH 32

18. Which of the below is a risk scoring tool used to predict the need to treat patients presenting with upper gastrointestinal bleeding?

- a. Meld score
- b. Geneva score
- c. PESI score
- d. Child-Pugh score
- e. Glasgow-Blatchford score

Please turn the page

Faculty of Health and Wellbeing
MSc Advanced Practice/Advanced Professional Development
Semester One Examination 2018/2019
Acute Medicine
Module No: HLT7089

19. An 89 year old lady is admitted from a residential home with acute onset of confusion and reduced appetite. On examination, her respiratory rate is 22/min, sats 96% on air, P127bpm reg, BP 98/53. Temp 38.5. The urine dipstick is positive for nitrites, protein, leucocytes and ketones. What is the likely cause of the confusion?

- a. Urosepsis
- b. Diabetic ketoacidosis
- c. Renal obstruction
- d. Stroke
- e. Pneumonia

20. The following medications are useful in symptom control in headaches, except:

- a. Paracetamol
- b. Ibuprofen
- c. Codeine
- d. Sumatriptan
- e. Diclofenac

21. A 46 year old lady presents with a history of vertigo and vomiting. Which of the following features would be most in keeping with a diagnosis of acute labyrinthitis?

- a. Evolving symptoms over weeks
- b. Ipsilateral sensorineal hearing loss
- c. Nystagmus worsened by change in position
- d. Precipitation by minor head injury
- e. Improvement in symptoms following Epley manoeuvre

Please turn the page

Faculty of Health and Wellbeing
MSc Advanced Practice/Advanced Professional Development
Semester One Examination 2018/2019
Acute Medicine
Module No: HLT7089

22. A 73 year old man presented after a single episode of unilateral weakness of the right arm that lasted an hour. On examination, his pulse was 70/minute and regular, and his BP was 165/100. There was no neurological deficit. His ABCD2 score was 7. What is his chance of having a stroke in the first week?

- a. 5%
- b. 10%
- c. 20%
- d. 30%
- e. 40%

23. A 72 year old man is admitted to AMU following a fall with head injury. There is no focal neurology. Which one of the following drug therapies would mandate computed tomography (CT) head scanning?

- a. Aspirin
- b. Ramipril
- c. Warfarin
- d. Atorvastatin
- e. Clopidogrel

24. A 31 year old man is admitted following sudden onset of severe occipital headache which he describes as being hit on the back of his head with a shovel. On examination, there is no abnormal neurology found. A plain CT brain is normal so a lumbar puncture is performed at 12 hours to eliminate a subarachnoid haemorrhage (SAH). Which of the below results would be positive for a Subarachnoid haemorrhage

- a. Raised red cell count and low glucose.
- b. Raised white cell count and raised xanthochromia.
- c. Low glucose and raised xanthochromia.
- d. Raised glucose and low neutrophil count.
- e. Raised xanthochromia and raised red cell count.

Please turn the page

Faculty of Health and Wellbeing
MSc Advanced Practice/Advanced Professional Development
Semester One Examination 2018/2019
Acute Medicine
Module No: HLT7089

25. An 83-year-old woman presented following an episode of unconsciousness. Her husband reported that, while standing in the kitchen, she had fallen to the ground and had been unresponsive for 1 minute. He noticed that his wife became very pale during the event and that there were several jerking movements of her left arm. Within 5 minutes of onset, she was conscious and orientated. She had experienced three similar episodes in the last 12 months. Examination was normal. An ECG revealed sinus rhythm and left axis deviation.

What investigation is most likely to lead to a correct diagnosis?

- a. 72 hour ambulatory ECG
- b. Ct Brain
- c. EEG
- d. ECHO
- e. Capillary blood glucose

26. A 77 year old lady was admitted with a right temporal headache and jaw claudication. On examination, she had a palpable tender right temporal artery. Her blood tests showed a raised ESR level. What would be the most likely diagnosis?

- a. Migraine
- b. Temporal arteritis
- c. Cerebral haemorrhage
- d. Transient Ischaemic Attack
- e. Psoriasis

Please turn the page

Faculty of Health and Wellbeing
MSc Advanced Practice/Advanced Professional Development
Semester One Examination 2018/2019
Acute Medicine
Module No: HLT7089

27. A 23 year old woman presents to the AMU with a rapidly evolving severe headache. She has a family history of neoplasm and she is worried that this could be the cause of her headaches. Which of these accompanying features would suggest a diagnosis other than a migraine?

- a. Asymmetrical reflexes
- b. Vomiting
- c. Unilateral site
- d. Photophobia
- e. Exacerbation by exercise

28. A 72 year old lady is admitted with a one week history of dizziness which is mainly of standing and when walking. She has a history of hypertension and has recently been started on an ACE inhibitor in addition to the Calcium channel blocker that she normally takes for her blood pressure. Her vital signs, blood tests and ECG are normal. What would be your next step in this patient's management?

- a. Lying and standing BP
- b. Urinary dipstick
- c. Discharge home
- d. ECHO
- e. Capillary blood glucose

Please turn the page

Faculty of Health and Wellbeing
MSc Advanced Practice/Advanced Professional Development
Semester One Examination 2018/2019
Acute Medicine
Module No: HLT7089

29. An 18 year old student has been home from university for 2 days. During this time he has developed drowsiness, fever and disorientation. On examination, he is photophobic, has marked neck stiffness, has a positive Kernigs sign and has started to develop a purpuric rash across his chest. He has no other focal neurological deficit. What is the most appropriate next course of action?
- a. Administer Intravenous Antibiotics
 - b. Arrange CT Brain with contrast
 - c. Carry out a lumbar puncture
 - d. Take blood for viral PCR test
 - e. Puncture one of the purpuric lesions for microscopic analysis

30. A 21 year old man presented to the Acute Medical Unit with a four week history of excessive thirst, urinary frequency and weight loss. His general practitioner had found his random blood glucose to be 26.0 mmol/L. On examination, his pulse was 80 beats per minute and his BP was 120/70 mmHg. His abdomen was soft, and not tender. Urinalysis showed ketones ++. The blood results returned as:

Na	141	(133 – 146)
K	4.9	(3.5 – 5.3)
Urea	16	(2.5 – 7.8)
Creat	82	(45 – 84)
Glucose	27.0	
Ph	7.29	(7.35 - 7.45)

What is the most appropriate next step in management?

- a. Intravenous insulin
- b. Long acting insulin
- c. Long acting insulin and discharge
- d. Intravenous insulin and intravenous fluids
- e. Short acting insulin and discharge for review next day

Please turn the page

Faculty of Health and Wellbeing
 MSc Advanced Practice/Advanced Professional Development
 Semester One Examination 2018/2019
 Acute Medicine
 Module No: HLT7089

31. You are asked to see a 63 year old lady who has just arrived on AMU who has been referred in by her GP with a three day history of vomiting. You decide to do a venous blood gas which shows:

		Normal Values
Ph	7.47	(7.35-7.45)
PO₂	2	(unable to calculate in venous gas sample)
PCO₂	5.8	(4.5 - 6)
HCO₃	27	(22 - 26)
BE	+5	(-2 - +2)

What does the sample indicate?

- Metabolic acidosis
 - Respiratory Acidosis
 - Metabolic alkalosis
 - Respiratory Alkalosis
 - Normal result
32. A 53 year old lady who is known to have CKD stage 3, is referred by her GP with intermittent palpitations, generalised weakness, nausea and exertional breathlessness. Her 12 lead ECG shows normal sinus rhythm with tented T waves. The blood tests return as:

Na	133	(133 – 146)
K	7.0	(3.5 – 5.3)
Urea	21	(2.5 – 7.8)
Creat	232	(45 – 84)

What is your immediate management of the hyperkalaemia?

- IV dextrose and insulin, and Calcium Carbonate
- IV fluids
- Calcium Resonium
- Encourage oral fluids
- IV dextrose and insulin

Please turn the page

Faculty of Health and Wellbeing
MSc Advanced Practice/Advanced Professional Development
Semester One Examination 2018/2019
Acute Medicine
Module No: HLT7089

33. Acute kidney disease can be classified as pre-renal, renal or post renal failure. Which of the following answers is correct?

- a. Vasculitis is a cause of post-renal failure
- b. ACE inhibitors are a cause of renal failure.
- c. Dehydration is a cause of post renal failure
- d. Renal stones are a cause of pre-renal failure
- e. Acute tubular necrosis is a cause of pre renal failure

34. A 73 year old man with gastric Ca is admitted with lethargy, muscle twitching and constipation. His corrected calcium level returns critically raised at 3.1. What is the most appropriate treatment?

- a. Intravenous saline rehydration and IV Biphosphonates
- b. Intravenous saline rehydration
- c. IV Biphosphonates
- d. Calcitonin and IV Biphosphonates
- e. Intravenous saline rehydration and Calcitonin

35. A 46 year old lady is referred to ambulatory care with fatigue and weight gain. The FBC, U&E, LFT and Calcium have returned normal. The other bloods are as below:

TSH	17	(0.4 - 4.0)
FT3	2.6	(3.5 – 7.8)
FT4	5.7	(9 – 24)

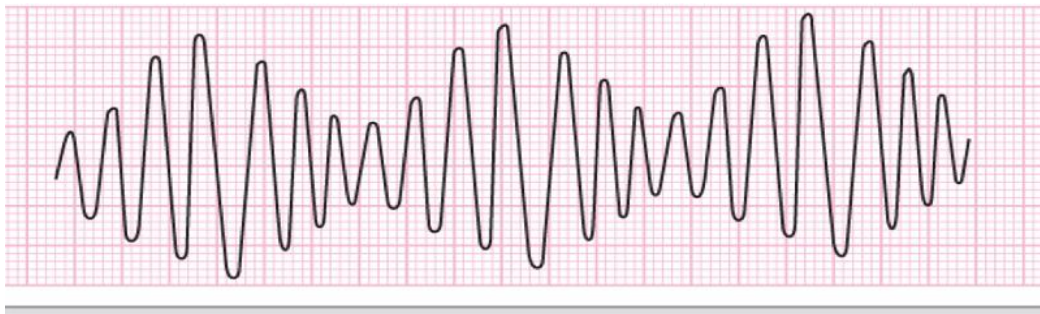
What would be the diagnosis?

- a. Hypoparathyroidism
- b. Hyperthyroidism
- c. Hyperparathyroidism
- d. Primary Hypothyroidism
- e. Secondary Hypothyroidism

Please turn the page

Faculty of Health and Wellbeing
MSc Advanced Practice/Advanced Professional Development
Semester One Examination 2018/2019
Acute Medicine
Module No: HLT7089

36. A 52 year old lady is referred with palpitations. The ECG monitor shows the rhythm below:



What is this rhythm?

- a. Supra-ventricular tachycardia
- b. Wenkebach
- c. Torsades de Pointes
- d. Mobitz Type II
- e. Mobitz Type I

37. Which of these is not a risk factor for developing DVT?

- a. Dehydration
- b. Pregnancy
- c. Hormone replacement therapy
- d. Inflammatory bowel syndrome
- e. Progesterone only oral contraceptive pill

Please turn the page

Faculty of Health and Wellbeing
MSc Advanced Practice/Advanced Professional Development
Semester One Examination 2018/2019
Acute Medicine
Module No: HLT7089

38. An 85-year-old man was admitted with increasing confusion, associated with a widespread blistering rash that had not responded to penicillin. On examination, his temperature was 38.0°C and there was a widespread macular rash with some blisters. There was no mucosal involvement.

What is the most likely cause of his rash?

- a. Bullous pemphigoid
- b. Dermatitis herpetiformis
- c. Drug reaction
- d. Pemphigus vulgaris
- e. Stevens-Johnson syndrome

39. A 32 year old lady with a raised BMI is admitted to the ambulatory care unit with a swollen, tender right calf. She has recently returned from Singapore and has sunburn but is otherwise well. She is on the oral contraceptive pill. Which is the most likely diagnosis?

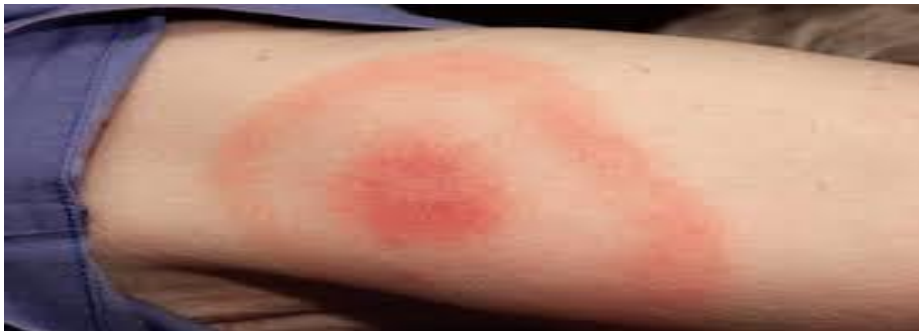- a. Calf muscle tear
- b. Cellulitis secondary to an insect bite
- c. Deep vein thrombosis
- d. Dependent oedema
- e. First degree burn (sun burn)

Please turn the page

PA

Faculty of Health and Wellbeing
MSc Advanced Practice/Advanced Professional Development
Semester One Examination 2018/2019
Acute Medicine
Module No: HLT7089

40. A 32 year old man was admitted with fever, rigors and generalized aches and pains. He is normally fit and well and had recently been walking in the New Forest. On examination his left lower leg was swollen with a clear demarcated area of erythema as below:



What is the most likely diagnosis?

- a. Atypical Eczema
 - b. Thrombophlebitis
 - c. Lyme disease
 - d. Cellulitis
 - e. Pemphigoid
41. A 36 year old lady presents with a five day history of lower back pain and leg numbness. She had been incontinent of urine which she was unaware of. She is currently receiving treatment for cervical cancer. On examination there is reduced power and tone to her lower limbs. What is the most appropriate diagnostic investigation?
- a. CT thorax, abdomen and pelvis
 - b. MRI spine
 - c. Calcium
 - d. Lumbar spine X-ray
 - e. Bone scan

Please turn the page

Faculty of Health and Wellbeing
MSc Advanced Practice/Advanced Professional Development
Semester One Examination 2018/2019
Acute Medicine
Module No: HLT7089

42. A 27 year old man presents with tiredness, weight loss and night sweats. The full blood count shows a low Hb at 78 and a raised white cell count. The blood film shows Blast cells. Which of the below answers could be a likely diagnosis?
- a. Viral illness
 - b. Haemolytic anaemia
 - c. Sideroblastic anaemia
 - d. Acute Myeloid Leukaemia
 - e. Pernicious anaemia
43. What treatment is recommended for use in staggered Paracetamol overdose?
- a. N- Acetylcysteine (Parvolex)
 - b. Activated Charcoal
 - c. Bicarbonate
 - d. Gastric lavage
 - e. Haemodialysis
44. Which of the below medications is a salicylate?
- a. Paracetamol
 - b. Morphine
 - c. Aspirin
 - d. Ibuprofen
 - e. Amitriptyline

Please turn the page

Faculty of Health and Wellbeing
MSc Advanced Practice/Advanced Professional Development
Semester One Examination 2018/2019
Acute Medicine
Module No: HLT7089

45. Which of the following statements about the role of the AMU coordinator is correct?
- Judges appropriateness of clinical referrals in association with the medical consultant
 - Decides best clinical placement on the ward for patient
 - Makes clinical decisions regarding fitness for transfer
 - Uses clinical knowledge regarding best ward placement on transfer from the AMU
 - All of the above
46. There is an increasing prevalence of patients with a terminal diagnosis who are presenting to the AMU. Which of the following statements are correct?
- Palliative patients with a non-cancer diagnosis are less likely to be referred to the palliative care team.
 - Palliative patients with a non-cancer diagnosis are as likely to be referred to the palliative care team.
 - All AMU staff are aware that non-cancer patients can be referred to the palliative care team
 - Non-cancer patients are not referred to the palliative care team
 - The Palliative care team do not provide services for non-cancer patients
47. Complete the following sentence:
- Within medical practice, autonomy is:
- The right of competent adults to make informed decisions about their own medical care
 - The distribution of health resources and the decision about who gets what treatment
 - An ethical and legal duty not to harm intentionally or unintentionally
 - Treating others equitably with fairness
 - Acting in the best interests/doing good for the patient

Please turn the page

Faculty of Health and Wellbeing
MSc Advanced Practice/Advanced Professional Development
Semester One Examination 2018/2019
Acute Medicine
Module No: HLT7089

48. When a Deprivation of liberty is in place, it may include the use of restraint on some patients. Which of the following is incorrect?
- a. Restraint is carried out to prevent a patient causing harm to themselves.
 - b. Restraint is only carried out as long as it is needed
 - c. Restraint is carried out to prevent a patient who does not have capacity from self discharging against medical advice
 - d. Restraint is carried out if the patient does not have capacity and is likely to cause harm to others
 - e. Restraint can be carried out to allow staff to carry out their duties more effectively
49. A discussion took place on how to improve the management of patients presenting with Acute Kidney Injury (AKI) and the development of an AKI care bundle was suggested. What best describes a care bundle?
- a. Interventions designed to ensure all steps are completed
 - b. A small group of evidence-based processes that, when performed collectively, improve outcomes
 - c. Steps in patient management that must be completed sequentially within a defined time period
 - d. A checklist of medical and nursing interventions
 - e. A series of processes that must be completed to ensure patient safety

Please turn the page

Faculty of Health and Wellbeing
MSc Advanced Practice/Advanced Professional Development
Semester One Examination 2018/2019
Acute Medicine
Module No: HLT7089

50. Which of the following statements about discharge planning is incorrect?

- a. Discharges that are planned late in the day may lead to unnecessary overnight stays in hospital
- b. Discharge planning is an ongoing process for identifying the services and support a person may need following discharge from hospital.
- c. Discharge planning is only the responsibility of the discharge coordinators
- d. All staff should be clear about responsibilities to ensure that bed capacity is available on all wards seven days a week
- e. Discharge planning should start on admission to hospital

END OF QUESTIONS

PAST EXAMINATION PAPER